

Supersaturated Hydrogen-Rich Water Hydrotherapy for Recovery of Acute Injury to the Proximal Phalanges on the 5th Toe: A Case Report

Alex Tarnava

Drink HRW

Background: Traditional treatments of soft tissue injuries (STIs) and some musculoskeletal injuries (MSK-Is) involves therapies such as the RICE protocol, which consists of rest, ice, compression and elevation for several days following acute trauma. Designed to improve comfort and reduce pain following traumatic injury, questions exist on the efficacy of RICE protocol; if it may in fact delay the rate of healing; and if it has any beneficial effect at all. Recently, a growing body of evidence has suggested molecular hydrogen therapy (H₂) as a potential adjuvant, or first line treatment, for numerous MSK-Is, STIs, and afflictions affecting the skin, both through topical administration and oral consumption. **Case report:** The recovery of a middle-aged male who suffered an injury to the proximal phalanges of the 5th toe of the right foot while kickboxing. The participant received four 25-minute hydrogen-rich hydrotherapy sessions in a super saturated solution with an average concentration approaching 8mg/L, on days 1,3,5,7 following injury. Recovery noted a rapid reduction in pain and swelling, a dramatic improvement in range of motion and ability to bear weight, and an ability to conduct limited activities after first treatment, including walking and modified exercise (i.e., boxing). **Conclusion:** This case is yet another indication that high-concentration hydrogen-rich hydrotherapy may be a helpful first line treatment in terms of reduction of pain and improvement in function following injury, in addition to the evidence suggesting benefit in reducing chronic indications caused by acute or chronic stress.

Citation

Tarnava, A. (2021). Supersaturated Hydrogen-Rich Water Hydrotherapy for Recovery of Acute Injury to the Proximal Phalanges on the 5th Toe: A Case Report. *Journal of Science and Medicine*; 3(1). <https://doi.org/10.37714/josam.v2i4.57>

Introduction

Musculoskeletal injuries (MSK-I) occur in elevated rates in athletes, with 76% of athletes assessed to have at least one injury during one cross-sectional study monitoring 627 athletes from five sports (rugby, soccer, combat sports, handball, and water polo), with the rate of injury 4–5 times higher in those above 30 years of age than those below [1]. MSK-I occurrence, particularly when a joint or bone is affected, may lead to other, more long-term and serious musculoskeletal disorders such as osteoarthritis, which occurs in a higher rate in the athletic population than the general population [2]. Standard treatments for MSK-I, such as rest, ice, compress, and elevate (RICE protocol), have insufficient evidence in order to determine benefit [3]. It has been suggested that the use of ice on soft tissue injuries (STIs) may not be advisable, due to reduction in blood flow and subsequent retardation of the healing process [4].

Molecular hydrogen therapy has recently emerged as a potential candidate for treating MSK-Is, with an early report demonstrating improvements in blood plasma flow and range of motion when

the use of both oral and topical administration of H₂ was given, as compared to standard care [5]. Further, a case report on a grade 2 ankle sprain in a professional soccer player found marked improvements in pain, swelling, and range of motion [6], with a subsequent clinical trial finding hydrogen-rich hydrotherapy to be equivalent to RICE protocol after multiple sessions in a single day in ankle sprains (n=18), with results trending to favour hydrogen-rich hydrotherapy, although not reaching statistical significance [7]. To date, no data is available on the effectiveness of hydrogen-rich hydrotherapy when administered across multiple days following injury, or on injured areas other than the ankle. This case report illustrates the potential safety and efficacy of the application of multiple-day, follow-up, hydrogen-rich hydrotherapy sessions following STI and potential fracture of the proximal phalanges.

Patient information

The case of a 35-year-old Caucasian male who suffered a sport-related injury while kickboxing, resulting in a potential fracture of the proximal phalanges on the 5th toe of his right foot, is the subject of this report. The patient was an apparently healthy middle-aged male participating in an activity he had significant experience (35 years of age, 98kg, 180cm, 11 years kickboxing) with no history of any broken or fractured bones in the past 12 months. The patient has no cardiometabolic issues; however, he has extensive osteoarthritis, most prevalently in the glenohumeral joint. No osteoarthritis or history of injury is present in the bone, or foot, which this injury occurred. Written informed consent was obtained from the patient for approval of use of this case study and the information and images presented.

Clinical findings

At initial assessment 2 hours following injury, the 5th toe of the left foot was significantly swollen and bruised (Figure 1, Panel A). The patient reported high pain, inability to bend the toe in question, and inability to bear weight on the toe in question. The patient reported increased, sharp, acute pain when the injured location was touched, specifically on the outside of the injured toe.

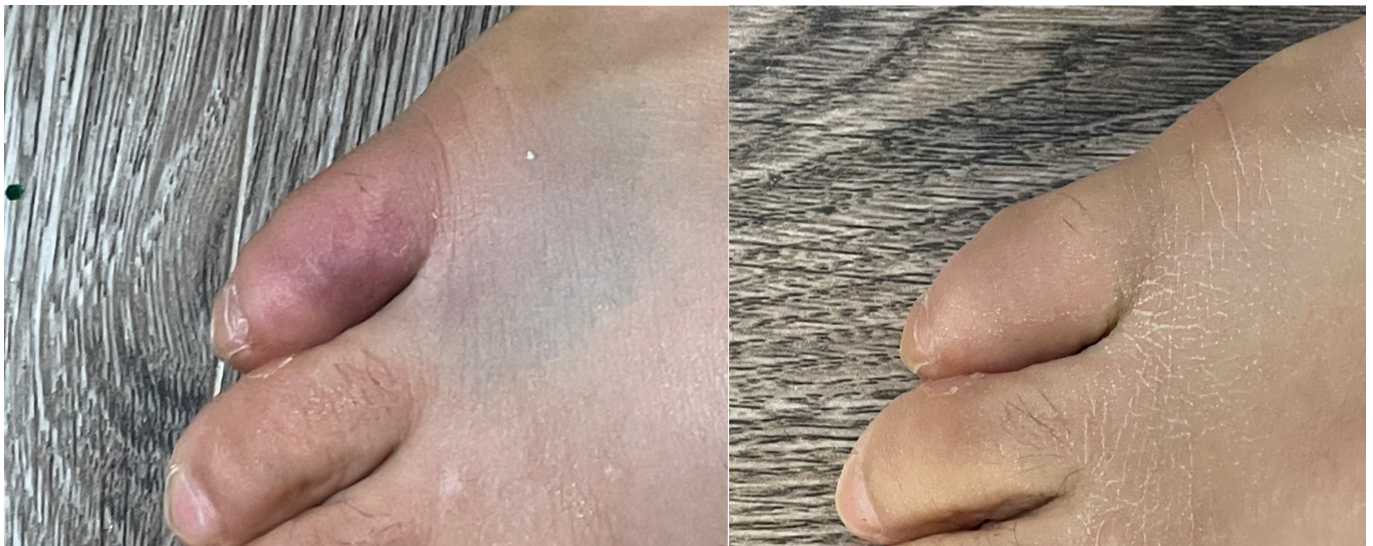


Figure 1.

An image of an injured toe: (a) Two hours after the injury; (b) At the 7-day follow-up after four 30-min sessions of hydrotherapy, days 1, 3, 5 and 7, with super-saturated hydrogen-rich water

Hydrogen therapy

A targeted hydrotherapy approach with super-saturated hydrogen-rich water was the exclusive treatment utilized during this period, with the aim to reduce symptoms and signs of injury while allowing limited activity. The patient opted against full rest, choosing to participate in boxing, regular walking, and performing household tasks as usual, but avoiding running, kickboxing, and skiing, all of which placed greater pressure on the injured toe. The patient noted greater pain and swelling the day after treatment, each day, when compared to immediately following treatment. Super-saturated hydrogen-rich water was produced by adding eight magnesium-based tablets into a 4L tub every 5 minutes for a total of 40 tablets utilized across 25 minutes. Each tablet weighed approximately 2g and contained 240mg of elemental magnesium. The starting water temperature utilized was within the standard room temperature range (25C); however, the exothermic nature of the reaction altered the water temperature, which was 30.1C at the end of the 25-minute session where measurements were obtained. Hydrogen was produced when elemental magnesium reacts with water by the following reaction: $Mg + H_2O \rightarrow H_2 + Mg(OH)_2$. Magnesium-based hydrogen-producing tablets were provided by Drink HRW (HRW Natural Health Products, New Westminster, BC, Canada). The concentration of hydrogen was measured in the water at the following time intervals: upon initial reaction and subsequent submersion of foot (~90 seconds), and then again at the following minute marks: 5, 6.5, 10, 11.5, 15, 16.5, 20, 21.5, and 25 minutes. In each case, the times were measured immediately before additional tablets were added and then once the tablets had finished reacting. Peak concentration exceeded 9.5-14mg/L, but fell to 3.5-5mg/L immediately before addition of the next eight tablets, with each concentration graphed at each time point in [Figure 2](#), yielding an expected average concentration of 7.86mg/L of molecular hydrogen throughout the 25-minute hydrotherapy session. Hydrogen concentration was determined using redox titration (H₂Blue; H₂Sciences, Las Vegas, Nevada). Throughout the 7-day intervention (including day of injury) the participant underwent a total of four 25-minute hydrogen-rich hydrotherapy sessions: on day 1, 2 hours following injury, and then in the morning of days 3, 5, and 7. During each session the entire foot was submerged, up to the ankle, in a bucket designed for foot baths. The water was still, receiving no turbulence or jetting. The participant elevated the foot in water just above the hydrogen tablets as they reacted, further allowing the gas production to come into direct contact with the injured toe. The hydrotherapies were formulated and supervised according to the manufacturer's recommendations, and in similar fashion to other human clinical research utilizing the same intervention for various other sports-related injuries.

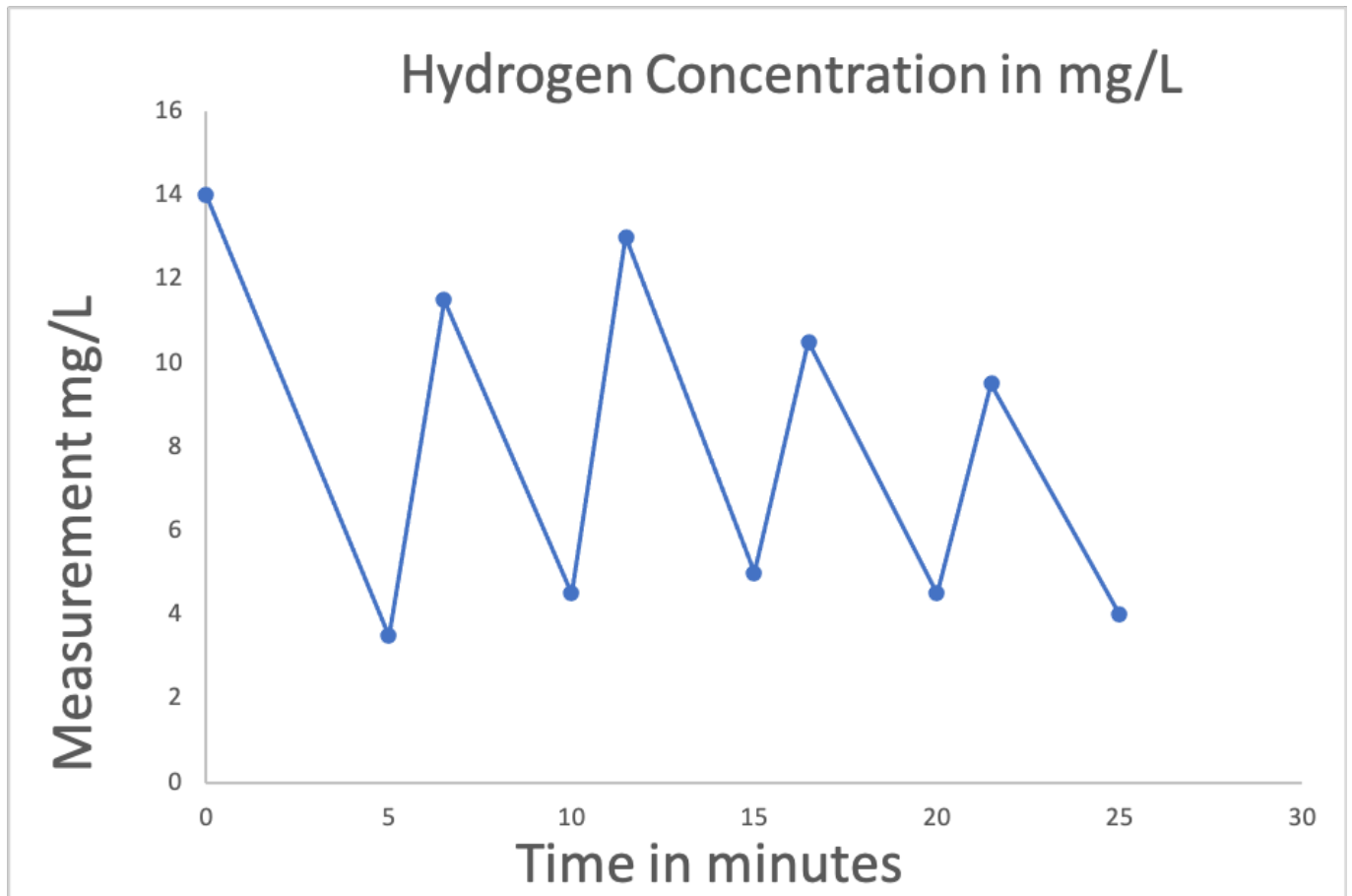


Figure 2.

Hydrogen concentration was measured at various time points during the 25-minute hydrotherapy session. Average concentration assumes linear increase in concentration throughout the 90-second tablet dissolution time, and linear descent from peak concentration until the next measurement. Each two-point time period was given a weighted average as % of total time to determine average concentration, as measurements between periods were not equidistant. Average concentration was determined to be 7.86 mg/L

Follow-up and outcomes

At the 7-day follow-up (Figure 1, Panel b), the participant reported significantly lower pain, full range of motion in the toe, ability to bear weight, and visual signs of swelling and bruising dramatically reduced. The participant did note that pain was still present, particularly when the outside of the toe experienced external force. The participant did not report any side effects from the hydrogen-rich hydrotherapy intervention.

Discussion

Molecular hydrogen therapy has emerged as a potential treatment option for numerous acute and chronic ailments due to its seeming ability to ameliorate the deleterious consequences of excess oxidative stress and inflammation [8,9]. Although the exact molecular mechanisms have yet to be elucidated, it has been proposed that molecular hydrogen may act in a similar fashion to hormetic stress [10], with its efficacy a potential result of evolutionary adaptation, as molecular hydrogen has played an integral role in our species, in fact all life, and our planet's, history [11]. Of note, other hormetic stressors such as cold exposure and heat exposure have been proposed, and are

widely used, in treatment of MSK-Is and STIs [12]. Conversely, chronic cold exposure is associated with a higher rate of musculoskeletal disorders [13]. Molecular hydrogen therapy is believed to have a much higher safety profile than other known hormetic stressors, with no biphasic response determined to date, as higher dosages tend to produce more significant results [11]. As such, exploration of various protocols regarding dosing and duration of exposure is warranted.

In this case study, the author endeavoured to produce a higher concentration of molecular hydrogen, administered across several days and sessions, than has previously been utilized in the pilot research for the treatment of STI. Peak concentrations were reported higher than previously reported, with the average concentration approaching the peak concentrations previously reported. One confounding variable exists in this approach, in that a total of 9.6g of magnesium was utilized in each bath, as compared to the 1.2g previously administered. Magnesium salts such as Epsom salts are widely used by the population; however the evidence regarding the transdermal bioavailability of magnesium is inconclusive [14] and the clinical benefits of bathing in Epsom salts is non-existent, as the only reported research has been published on commercial websites and not subjected to the peer review process [14]. The use of molecular hydrogen for MSK-Is and STIs deserves significant attention. Of note, the first case report of magnesium metal implants yielding beneficial outcomes following surgical use dates back to 1878, with active biomedical implant research being conducted in modern times exploring the use of magnesium metal-based implants, with reports suggesting most patients experience significant benefits, such as no pain and no infection during the post-operative follow-up [15]. Of course, H₂-based gas cavities are formed around the rapidly disintegrating magnesium-based implants [16], with the benefits of magnesium-based implants likely attributable to the increased hydrogen exposure.

MSK-Is have the potential to cause numerous long-lasting consequences, such as permanent damage to the soft tissue or nerves, or increased rate of degeneration. Molecular hydrogen has previously demonstrated the ability to reduce cartilage damage in rodent models of osteoarthritis [17-19] and osteonecrosis [20] via inhibition of oxidative stress, apoptosis, and catabolism and suppression of activated Wnt/ β -catenin signalling. Hydrogen-rich mediums have further shown to protect chondrocytes from oxidative stress [21] and abate bone loss suffered by microgravity [22]. Further, hydrogen-producing magnesium metal has been reported to improve peripheral nerve repair [23], and consumption of hydrogen-rich water has been reported as effective in accelerating oral palatal wound healing [24]. In humans, topical hydrotherapy has been shown to ameliorate delayed onset muscle soreness [25,26], address excess inflammation in psoriasis [27], and improve outcomes regarding wrinkle formations [28] and UV damage [29] via reduction of oxidative stress. Although there is no available data regarding the bioavailability of molecular hydrogen when applied topically, previous reports suggest it is highly bioavailable via this route. This is not surprising due to its small size and high rate of diffusion through tissues and cells [30]. It has previously been proposed that topical hydrogen may easily be transported to hard-to-reach tissues, which include areas of injury that often suffer from low drug penetrability [6]. Molecular hydrogen therapy holds the potential to not only treat the acute effects of STIs and MSK-Is, but to ameliorate the long-term damage arising from toxic by-products of the injuries. Further, well-controlled research is highly warranted.

Limitations

Several limitations must be considered when the study findings are interpreted. First, the magnesium content in the water was not controlled for, and this is a single, unblinded noncontrolled case report that the author performed on himself. Second, only limited visual and experiential outcomes were recorded and analyzed, with no analysis of any biomarkers or imaging to determine extent of damage to the bone. Third, there is no knowledge on the extent of transdermal bioavailability of topical exposure to hydrogen-rich hydrotherapy, which has no published knowledge or comparisons in C_{max} as compared to other molecular hydrogen delivery options, such as oral consumption of hydrogen-rich water, hydrogen inhalation, or hydrogen-rich saline. Further, the injury was suffered in the afternoon of the 23rd of December, and due to the

ongoing Covid-19 pandemic combined with non-emergency clinics being closed for the Christmas holidays, in-person evaluation by a medical doctor and medical imaging were not performed. Determination on extent of, or existence of a fracture or break to the bone in question is impossible due to lack of X-Ray imaging. Finally, it is yet unknown how molecular hydrogen therapy will affect other MSK-Is and STIs, and which route of delivery, at what concentration and dosage, and for what treatment duration, is optimal.

Conclusions

Despite these results being based on a single patient report with several limitations in affirmation of extent of injury and objective biomarker analysis, the suggested outcomes are in line with the empirical evidence published across other similar studies, both in laboratory animals and in humans. Hydrogen-rich hydrotherapy is demonstrating to be a safe and effective treatment option in the amelioration of the acute and chronic deleterious effects of STIs and MSK-Is and warrants further research and attention in order to determine the extent of beneficial results.

Consent

Written informed consent was obtained from the patient for the publication of this case report, including any associated images.

Competing Interests

The author is employed by, and has financial interest in, commercial entities involved in the development and distribution of molecular hydrogen products intended for therapeutic benefits.

References

1. Goes Rodrigo Araújo, Lopes Lucas Rafael, Cossich Victor Rodrigues Amaral, de Miranda Vitor Almeida Ribeiro, Coelho Olívia Nogueira, do Carmo Bastos Ricardo, Domenis Letícia Aparecida Marincolo, Guimarães João Antonio Matheus, Grangeiro-Neto João Alves, Perini Jamila Alessandra. Musculoskeletal injuries in athletes from five modalities: a cross-sectional study. *BMC Musculoskeletal Disorders*. 2020; 21(1)[DOI](#)
2. Amoako Adaye O., Pujalte George Guntur A.. Osteoarthritis in Young, Active, and Athletic Individuals. *Clinical Medicine Insights: Arthritis and Musculoskeletal Disorders*. 2014; 7[DOI](#)
3. van den Bekerom Michel P.J., Struijs Peter A.A., Blankevoort Leendert, Welling Lieke, van Dijk C. Niek, Kerkhoffs Gino M.M.J.. What Is the Evidence for Rest, Ice, Compression, and Elevation Therapy in the Treatment of Ankle Sprains in Adults?. *Journal of Athletic Training*. 2012; 47(4)[DOI](#)
4. Bleakley Chris, McDonough Suzanne, MacAuley Domhnall. The Use of Ice in the Treatment of Acute Soft-Tissue Injury. *The American Journal of Sports Medicine*. 2004; 32(1)[DOI](#)
5. Ostojic Sergej M., Vukomanovic Boris, Calleja-Gonzalez Julio, Hoffman Jay R.. Effectiveness of Oral and Topical Hydrogen for Sports-Related Soft Tissue Injuries. *Postgraduate Medicine*. 2014; 126(5)[DOI](#)
6. Javorac Dejan, Stajer Valdemar, Ostojic Sergej. Case Report: Acute hydrotherapy with super-saturated hydrogen-rich water for ankle sprain in a professional athlete. *F1000Research*. 2020; 9[DOI](#)
7. Javorac Dejan, Stajer Valdemar, Ratgeber Laszlo, Olah Andras, Betlehem Jozsef, Acs Pongras, Vukomanovic Boris, Ostojic Sergej M.. Hydrotherapy with hydrogen-rich water compared with RICE protocol following acute ankle sprain in professional athletes: a randomized non-inferiority pilot trial. *Research in Sports Medicine*. 2020. [DOI](#)
8. LeBaron Tyler W., Kura Branislav, Kalocayova Barbora, Tribulova Narcis, Slezak Jan. A New

- Approach for the Prevention and Treatment of Cardiovascular Disorders. Molecular Hydrogen Significantly Reduces the Effects of Oxidative Stress. *Molecules*. 2019; 24(11)[DOI](#)
9. Ge Li, Yang Ming, Yang Na-Na, Yin Xin-Xin, Song Wen-Gang. Molecular hydrogen: a preventive and therapeutic medical gas for various diseases. *Oncotarget*. 2017; 8(60)[DOI](#)
 10. LeBaron Tyler W., Laher Ismail, Kura Branislav, Slezak Jan. Hydrogen gas: from clinical medicine to an emerging ergogenic molecule for sports athletes. *Canadian Journal of Physiology and Pharmacology*. 2019; 97(9)[DOI](#)
 11. T. Tarnava Alex. EVOLUTION, ADAPTIVE STRESSORS AND MOLECULAR HYDROGEN. *International Journal of Advanced Research*. 2020; 8(11)[DOI](#)
 12. Malanga Gerard A., Yan Ning, Stark Jill. Mechanisms and efficacy of heat and cold therapies for musculoskeletal injury. *Postgraduate Medicine*. 2014; 127(1)[DOI](#)
 13. Pienimäki Tuomo. Cold exposure and musculoskeletal disorders and diseases. A review. *International Journal of Circumpolar Health*. 2002; 61(2)[DOI](#)
 14. Gröber Uwe, Werner Tanja, Vormann Jürgen, Kisters Klaus. Myth or Reality—Transdermal Magnesium?. *Nutrients*. 2017; 9(8)[DOI](#)
 15. Witte Frank. The history of biodegradable magnesium implants: A review. *Acta Biomaterialia*. 2010; 6(5)[DOI](#)
 16. Kuhlmann Julia, Bartsch Ivonne, Willbold Elmar, Schuchardt Sven, Holz Olaf, Hort Norbert, Höche Daniel, Heineman William R., Witte Frank. Fast escape of hydrogen from gas cavities around corroding magnesium implants. *Acta Biomaterialia*. 2013; 9(10)[DOI](#)
 17. Cheng ShaoWen, Peng Lei, Xu BaiChao, Chen WenSheng, Chen YangPing, Gu YunTao. Protective Effects of Hydrogen-Rich Water Against Cartilage Damage in a Rat Model of Osteoarthritis by Inhibiting Oxidative Stress, Matrix Catabolism, and Apoptosis. *Medical Science Monitor*. 2020; 26[DOI](#)
 18. Wan Wei-Lin, Lin Yu-Jung, Shih Po-Chien, Bow Yu-Ru, Cui Qinghua, Chang Yen, Chia Wei-Tso, Sung Hsing-Wen. An In Situ Depot for Continuous Evolution of Gaseous H₂ Mediated by a Magnesium Passivation/Activation Cycle for Treating Osteoarthritis. *Angewandte Chemie International Edition*. 2018; 57(31)[DOI](#)
 19. Lin Yingni, Ohkawara Bisei, Ito Mikako, Misawa Nobuaki, Miyamoto Kentaro, Takegami Yasuhiko, Masuda Akio, Toyokuni Shinya, Ohno Kinji. Molecular hydrogen suppresses activated Wnt/ β -catenin signaling. *Scientific Reports*. 2016; 6(1)[DOI](#)
 20. Li Jia, Ge Zhaogang, Fan Lihong, Wang Kunzheng. Protective effects of molecular hydrogen on steroid-induced osteonecrosis in rabbits via reducing oxidative stress and apoptosis. *BMC Musculoskeletal Disorders*. 2017; 18(1)[DOI](#)
 21. Hanaoka Teruyasu, Kamimura Naomi, Yokota Takashi, Takai Shinro, Ohta Shigeo. Molecular hydrogen protects chondrocytes from oxidative stress and indirectly alters gene expressions through reducing peroxynitrite derived from nitric oxide. *Medical Gas Research*. 2011; 1(1)[DOI](#)
 22. Sun Y., Shuang F., Chen D. M., Zhou R. B.. Treatment of hydrogen molecule abates oxidative stress and alleviates bone loss induced by modeled microgravity in rats. *Osteoporosis International*. 2012; 24(3)[DOI](#)
 23. Tamaki Naofumi, Orihuela-Campos Rita Cristina, Fukui Makoto, Ito Hiro-O. Hydrogen-Rich Water Intake Accelerates Oral Palatal Wound Healing via Activation of the Nrf2/Antioxidant Defense Pathways in a Rat Model. *Oxidative Medicine and Cellular Longevity*. 2016; 2016[DOI](#)
 24. Vennemeyer JJ, Hopkins T, Hershcovitch M, Little KD, Hagen MC, Minter D, Hom DB, Marra K, Pixley SK. Initial observations on using magnesium metal in peripheral nerve repair. *Journal of Biomaterials Applications*. 2014; 29(8)[DOI](#)
 25. Tamaki Naofumi, Orihuela-Campos Rita Cristina, Fukui Makoto, Ito Hiro-O. Hydrogen-Rich Water Intake Accelerates Oral Palatal Wound Healing via Activation of the Nrf2/Antioxidant Defense Pathways in a Rat Model. *Oxidative Medicine and Cellular Longevity*. 2016; 2016[DOI](#)
 26. Todorovic Nikola, Javorac Dejan, Stajer Valdemar, Ostojic Sergej M.. The Effects of Supersaturated Hydrogen-Rich Water Bathing on Biomarkers of Muscular Damage and Soreness Perception in Young Men Subjected to High-Intensity Eccentric Exercise. *Journal*

- of Sports Medicine*. 2020; 2020[DOI](#)
27. Zhu Qinyuan, Wu Yueshen, Li Yongmei, Chen Zihua, Wang Lanting, Xiong Hao, Dai Erhong, Wu Jianhua, Fan Bin, Ping Li, Luo Xiaoqun. Positive effects of hydrogen-water bathing in patients of psoriasis and parapsoriasis en plaques. *Scientific Reports*. 2018; 8(1)[DOI](#)
 28. Kato Shinya, Saitoh Yasukazu, Iwai Keizou, Miwa Nobuhiko. Hydrogen-rich electrolyzed warm water represses wrinkle formation against UVA ray together with type-I collagen production and oxidative-stress diminishment in fibroblasts and cell-injury prevention in keratinocytes. *Journal of Photochemistry and Photobiology B: Biology*. 2012; 106[DOI](#)
 29. Shin Mi Hee, Park Raeun, Nojima Hideo, Kim Hyung-Chel, Kim Yeon Kyung, Chung Jin Ho. Atomic Hydrogen Surrounded by Water Molecules, H(H₂O)_m, Modulates Basal and UV-Induced Gene Expressions in Human Skin In Vivo. *PLoS ONE*. 2013; 8(4)[DOI](#)
 30. Ohta Shigeo. Recent Progress Toward Hydrogen Medicine: Potential of Molecular Hydrogen for Preventive and Therapeutic Applications. *Current Pharmaceutical Design*. 2011; 17(22)[DOI](#)