

# Case Report: Treatment of Lateral Epicondylitis with PEMF

*Sara Alfaro*

A male patient presented with lateral epicondylitis (tennis elbow). The condition had persisted for a period of 5 months. Prior to PEMF treatment, the patient had received multiple injections of steroids which had not been effective for the patient's pain and limited mobility of the left elbow. After a 4 week long treatment with a portable PEMF device (Micro-Pulse ICES Model A9), the patient's pain was resolved. Brain Gauge® scores, obtained at days 1, 27 and 40 throughout the duration of the PEMF treatment period, demonstrated significant improvement and paralleled the patient's report that his pain and mobility issues had been resolved with PEMF.

---

## Introduction

Lateral epicondylitis is a tendinopathy injury due to overuse of the elbow. Degeneration of attachment of the tendon where the extensor muscles of the forearm which originate weakens the anchor site, destabilizing the joint, and providing stress on the area. Associated pain can lead to difficulty performing normal daily tasks that involve lifting, gripping and grasping. Standard treatment involves activity modification and limitation of the injury-causing activity, bracing, physical therapy, and for more persistent pain, anti-inflammatory injections targeted at the afflicted area.

Pulse Electromagnetic Field (PEMF) has been used for several decades as a treatment modality for cellular regeneration and repair. While the biophysical mechanisms of action of PEMF remain unclear, the use of PEMF for the treatment of orthopedic pain and injury is gaining popularity as a non-invasive modality. The device used by this patient was developed based on a technology originally developed for NASA (Ref). During subsequent development, the core PEMF technology has been shown to reduce inflammation in a rat-carageenan model (manuscript in preparation). Having been refined and optimized for use with focal orthopedic injury, unlike typical "whole-body" PEMF systems, the wearable device reported here is specifically used for focal applications only on areas that cause pain.

## Case Presentation

A male patient (in his 40s) presented with acute pain due to lateral epicondylitis. Specifically, the patient experienced pain with pronation and supination. Following unsuccessful attempts to moderate his pain with injections of steroids, the patient sought out alternative treatment methods.

A series of 4 prolozone™ injections were administered across a 12 week period. In addition to the injections, the patient completed a physical therapy program. At the conclusion of the program, the patient experienced improvement in his pain from VAN 9-10 to a VAN 6-7 (these values were obtained using the visual analog scale for pain), but complained of persistent localized pain and limited range of motion.

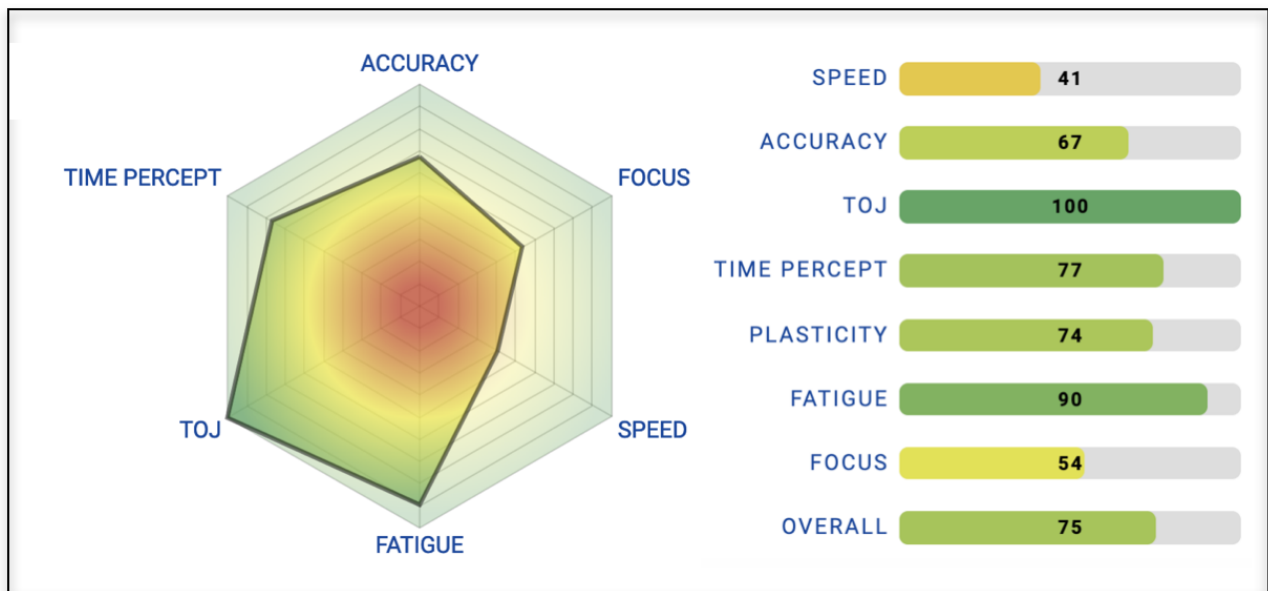
A 4 week period of PEMF treatment was instituted. The micro-pulse PEMF device was applied to the area and for treatment sessions of duration 60 minutes, 5 days weekly, for 4 weeks. The device was used on the medium intensity setting for the duration of the treatment period. Brain Gauge®

scores were obtained throughout the treatment period at 1 day of treatment, 27 days and 40 days. The wearable PEMF device employs a specific form of PEMF wherein pulse shape is controlled to maximize inductive coupling to the deep tissues in the area where the device is applied. This technology is designated ICES (R). (ICES: Inductively Coupled Electrical Stimulation). The system employs various pulse patterns including 10 and 100 pulses per second with a pulse period of 100 micro-seconds.

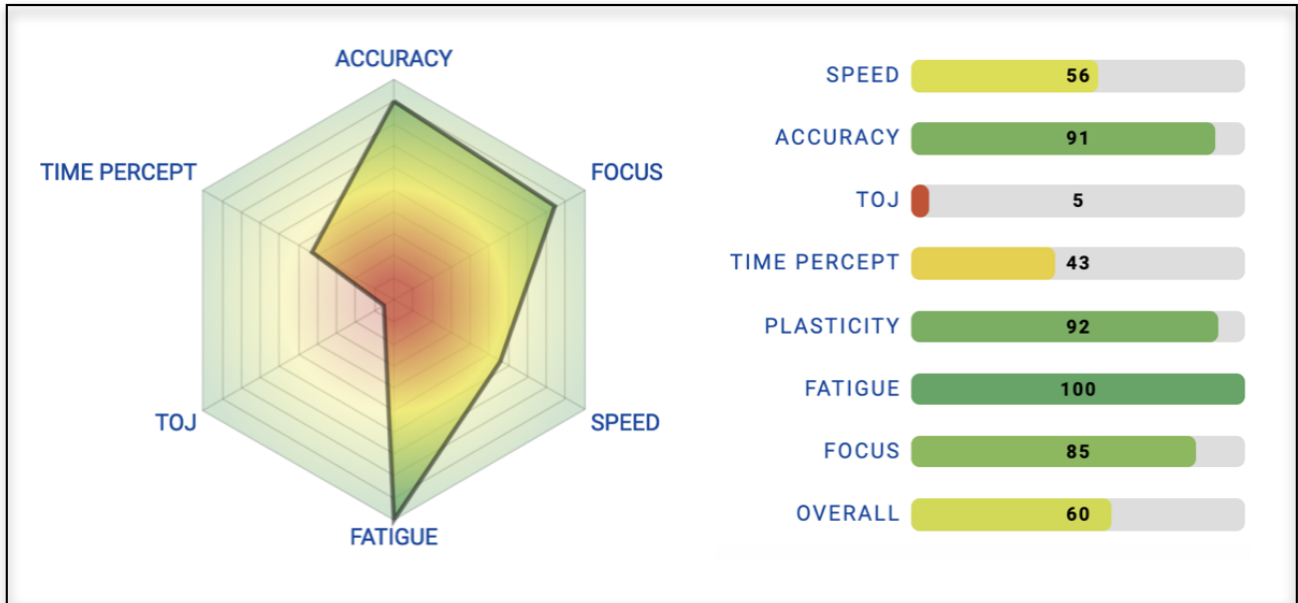
## Results

The prolozone injections improved the pain level in a stepped up fashion in a long period of 12 weeks from VN 9-10 to VAN 7 but then experienced a plateau with no more improvement. Following the 4 week long treatment period with PEMF, the patient’s pain decreased substantially. From a VAN 7 to a VAN 2 and disappearing completely and was able to return fully to work activities and all his ADL. Note the progression of Brain Gauge® scores from Figures 1 to 3 - a significant improvement in scores is demonstrated over the time period of treatment.

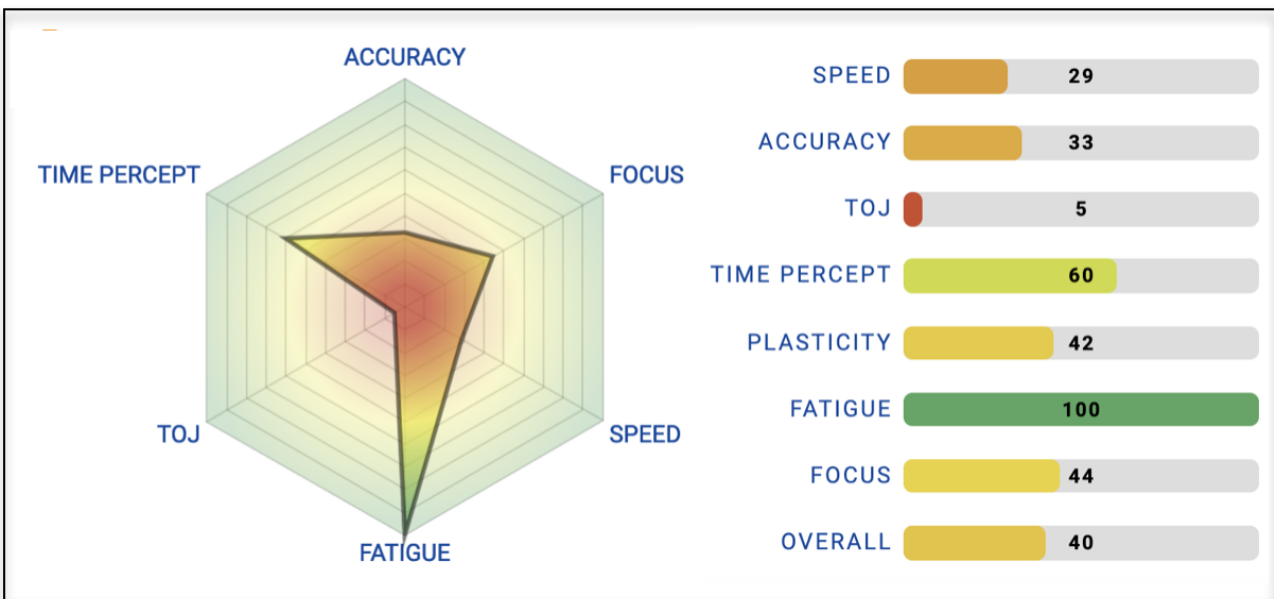
The patient stated that he believed that PEMF was the treatment that was most effective for his pain and mobility issues and did not return for follow-up treatment.



**Figure 1.** Pre-Treatment Brain Gauge® scores.



**Figure 2.** Post-Treatment (Day 27) Brain Gauge® scores.



**Figure 3.** Post-Treatment (Day 40) Brain Gauge® scores.

## Discussion

PEMF administration has been demonstrated to have a significant impact on pain and inflammation across a wide spectrum of conditions for several decades (Hubbard & Dennis, 2012; Ravid, 2019) and although not widely used in traditional medical practice, there has been a growing and significant interest in its utilization as a therapy. The case study presented in this report is but one example of successful PEMF administration to treat pain. A larger cohort of patients responding positively to PEMF treatment is documented in a recent dissertation by Stacey Ravid (Ravid, 2019).

The difference between this case study and the examples in that body of work is that this report provides observations of changes in brain health, as measured by the Brain Gauge. Pain has a significant impact on brain function and in particular, somatosensory function as it is evaluated with the Brain Gauge (Nguyen, et al, 2013; Zhang et al, 2011; Whitsel et al, 2019). Thus, the improvement in Brain Gauge scores is an anticipated outcome from decreasing a patient's pain. It is anticipated that future case studies will be reported with similar outcomes, and because the Brain Gauge provides an objective assessment of the patient's brain health, a compilation of those case studies in a future report will be able to document the overall effectiveness of PEMF on different types of pain and the impact that pain has on a patient's well-being.

## Conclusions

This case study is but one illustration of the potential utility of PEMF in the clinical setting for treatment of pain and chronic non resolved inflammatory conditions. While it is not clear if the previous treatments with ozone played a role in the subsequent success in treating the patient's pain with PEMF, it is possible that the effects of PEMF can be bolstered when delivered in combination with bioregulatory treatments, such as ozone, to moderate pain. PEMF was effective in resolving the pain in this patient and the Brain Gauge was an effective tool in tracking and quantifying the outcome.

## References

1. Hubbard, D. K., & Dennis, R. G. Pain relief and tissue healing using PEMF therapy: A review of stimulation waveform effects. *Asia Health Care Journal*, 1(1), 26-35. (2012).
2. Nguyen, R. et al. An undergraduate laboratory exercise to study sensory inhibition. *J. Undergrad. Neurosci. Educ.* JUNE Publ. FUN Fac. Undergrad. Neurosci. 11, A169-173 (2013).
3. Ravid, S. Descriptive Exploratory Study of Individuals' Use of Pulsed Electromagnetic Fields, The Micro-Pulse, for Pain Relief. The Christine E. Lynn College of Nursing, Florida Atlantic University. (2019).
4. Whitsel, B., Vierck, C., Walters, R., Tommerdahl, M., Favorov, O. Contributions of Nociceptive Area 3a to Normal and Abnormal Somatosensory Perception. *Journal of Pain*. 20, 405-419, (2019).
5. Zhang, Z., Francisco, E., Holden, J., Dennis, R. & Tommerdahl, M. Somatosensory Information Processing in the Aging Population. *Front. Aging Neurosci.* 3, (2011).